Seated & Standing OMT

Jay B. Danto, D.O.

KCU – Joplin Campus

Associated Professor, Chair

Disclosure Information

KAOM Annual Conference 2018 – "Seated & Standing OMT"
Jay B. Danto, DO

- I have no financial relationships to disclose.
- I will not discuss off label use and/or investigational use in my presentation.


Kansas City University

Diagnosis and Treatment of the C-spine

Seated & Standing OMT

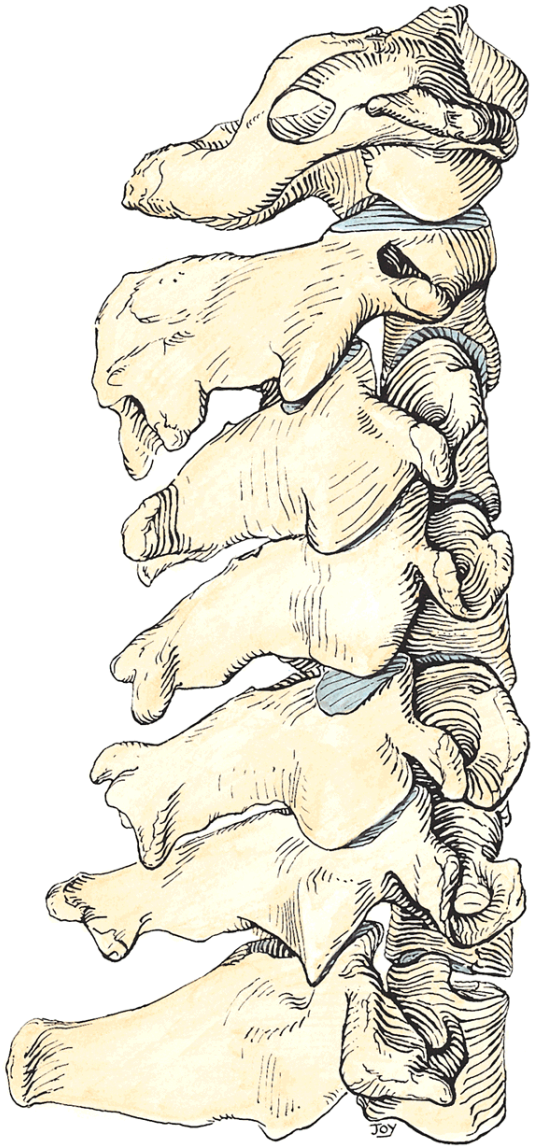

Kansas City University
OF MEDICINE AND BIOSCIENCES

Barriers to ROM



AB – Anatomic Barrier

PB – Physiologic Barrier

Barriers to ROM

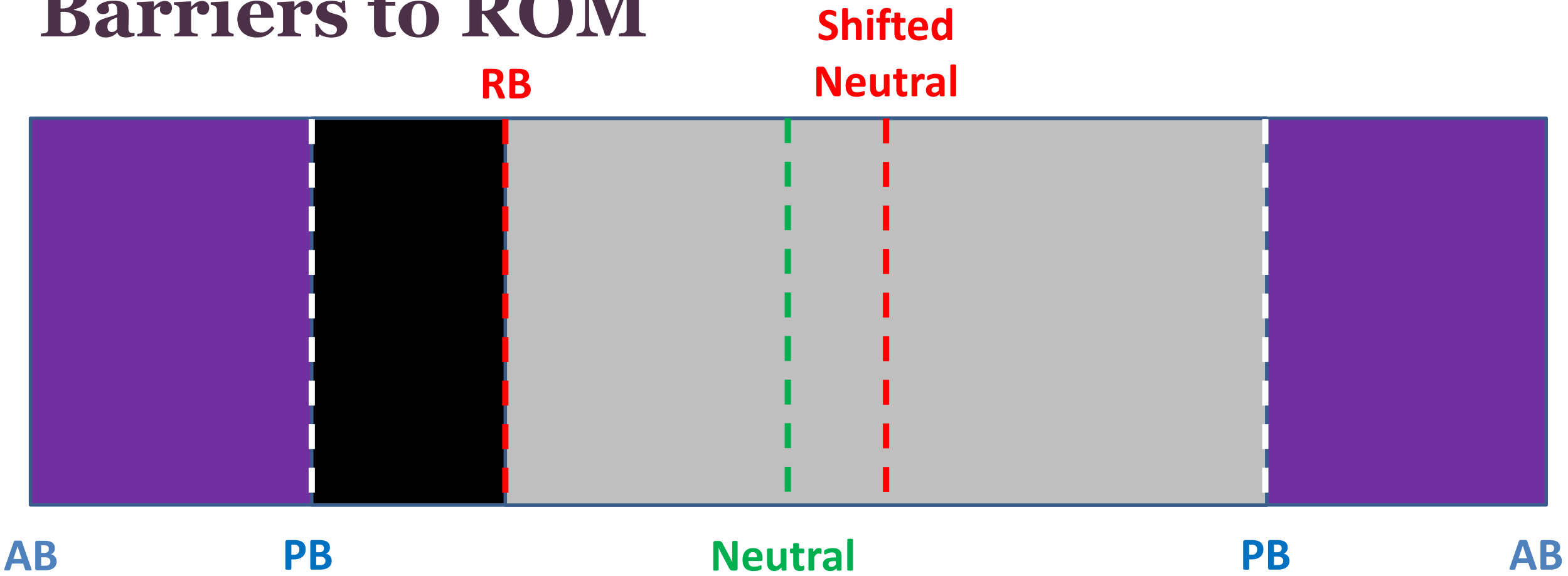

AB – Anatomic Barrier

RB – Restrictive Barrier

PB – Physiologic Barrier

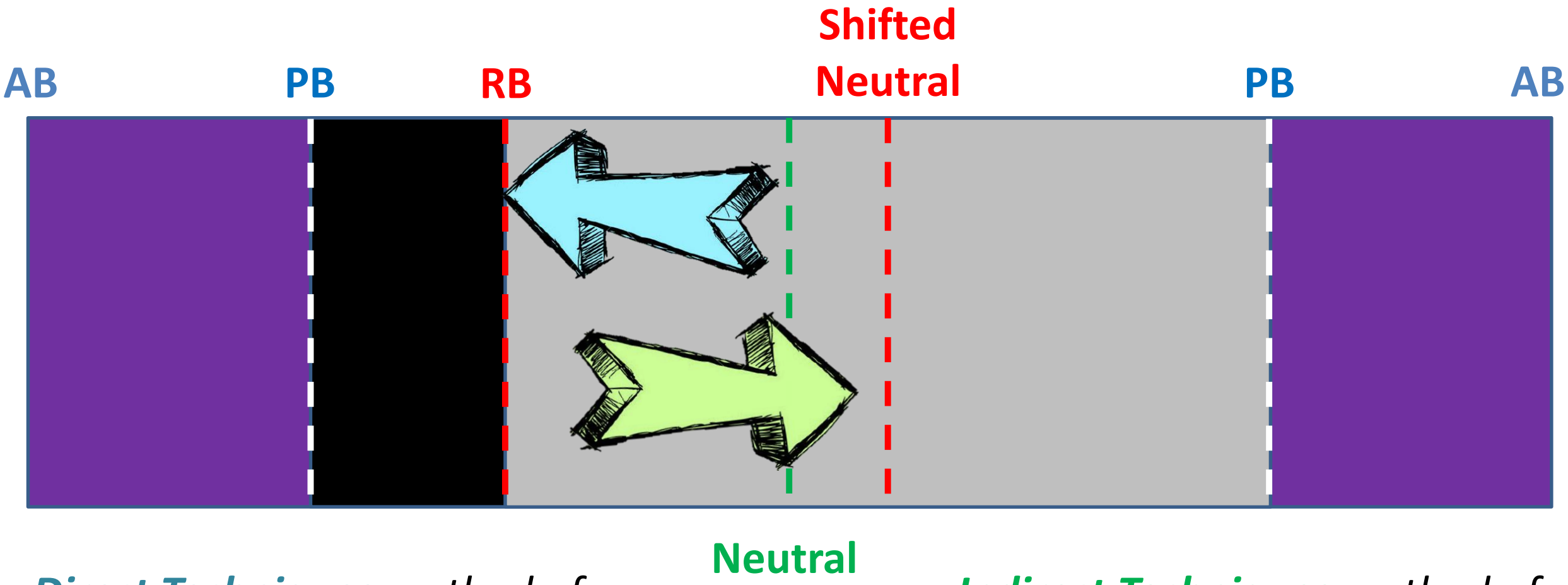

Direct Techniques *method of action engage the restrictive barrier directly.*

Indirect Techniques *method of action involve positioning away from the restrictive barrier.*

AA Biomechanical Evaluation – Palpatory/Visual

- **Flex** the patient's head maximally to lockout the vertebrae below
- **Monitor** the suboccipital area with your pads of your thumb and index finger *(Optional)*
- **Evaluate rotation** introduced using your other hand on the crown of the patient's head
  - *Restricted motion is palpated by the monitoring fingers with TTA and observed visually*
  - ***Segmental definition*** .

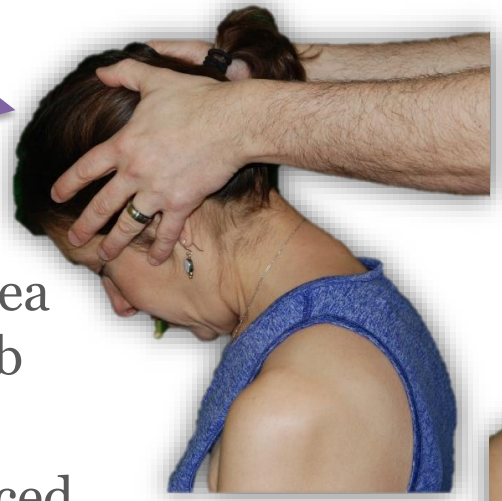

Left Rotation

Right Rotation

Muscle Energy Technique Definition

- Characterized as a specific, non-repetitive articulatory method that is indirect, then direct.
- Attributed to A.T. Still.
- A term coined by Richard Van Buskirk, DO, PhD.

Glossary of Osteopathic Terminology (2011)

Muscle Energy Technique

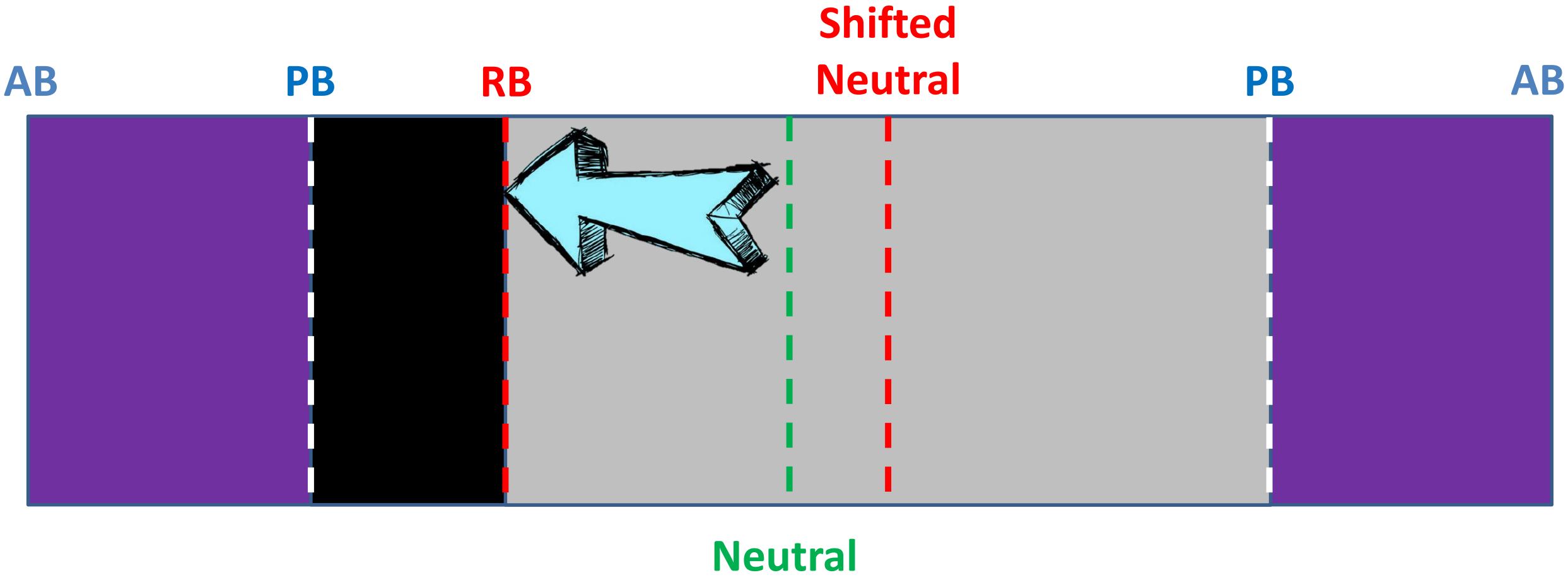

*Position the somatic dysfunction to engage the RB **Directly** & use patient directed muscle activation away from the RB.*

AA MET

- **Flex** the patient's head maximally to lockout the vertebrae below
- **Monitor** the suboccipital area with your pads of your thumb and index finger *(Optional)*
- **Engage the RB**
- **3-5 patient directed rotation away from the RB**
- **Recheck**.

Alternate monitoring option

3-5 reps

Starting at Rotation Right RB

Finish Position

OA Biomechanical Evaluation - Visual

- **Initial Assessment:** observe for symmetry of the patient regarding
  - ***Rotation:*** *assessed by alignment of the chin & nose with the midline*
  - ***Sidebending:*** *assessed by noting the ear to shoulder distances; level of their eyes in relation to the horizon*
  - *Note: sidebending and rotation should be in opposite directions*
- **Evaluate flexion & extension** response by asking the patient to first *nod* their head down and then up
- **Segmental definition** is defined by the direction of the nod that creates more symmetry of the ladnmarks..



Fulcrum

Principles of Seated Cervical Biomechanical Diagnosis

- **Monitor** the lateral aspect of the vertebral column with your ipsilateral index finger pad
  - *Your finger pad acts like a fulcrum*
- **Evaluate sidebending** introduced using your other hand on the crown of the patient's head
  - *Restricted motion palpated by the monitoring finger with TTA and inability of the vertebra to increase their sidebending angular relationship indicates somatic dysfunction*
- **Segmental definition** by response to SB in flexion and extension.

Neutral, setup

Sidebending

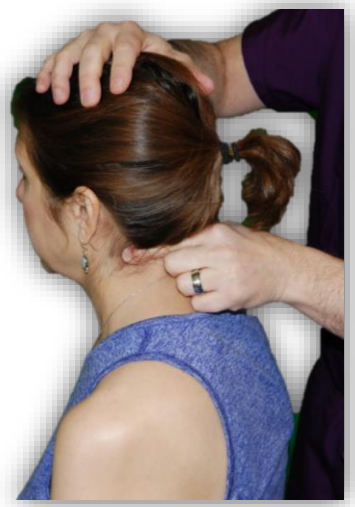

Neutral, setup

Flexion

Extension

Still Technique Definition

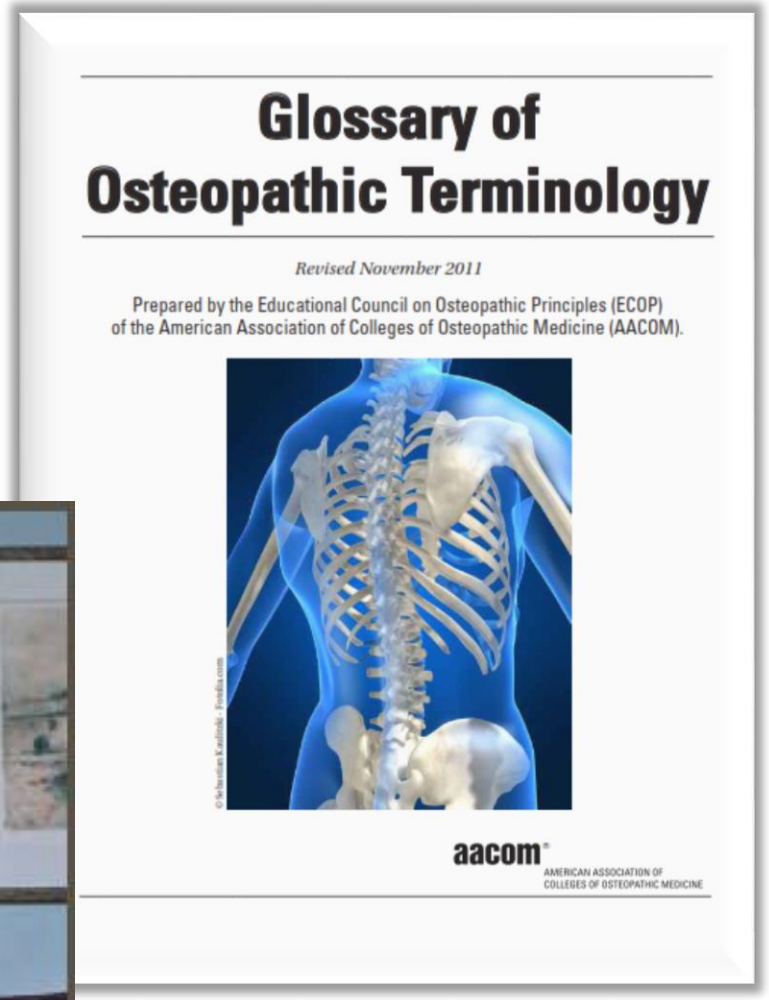

- Characterized as a specific, non-repetitive articulatory method that is indirect, then direct.
- Attributed to A.T. Still.
- A term coined by Richard Van Buskirk, DO, PhD.

Glossary of Osteopathic Terminology (2011)

Still Technique

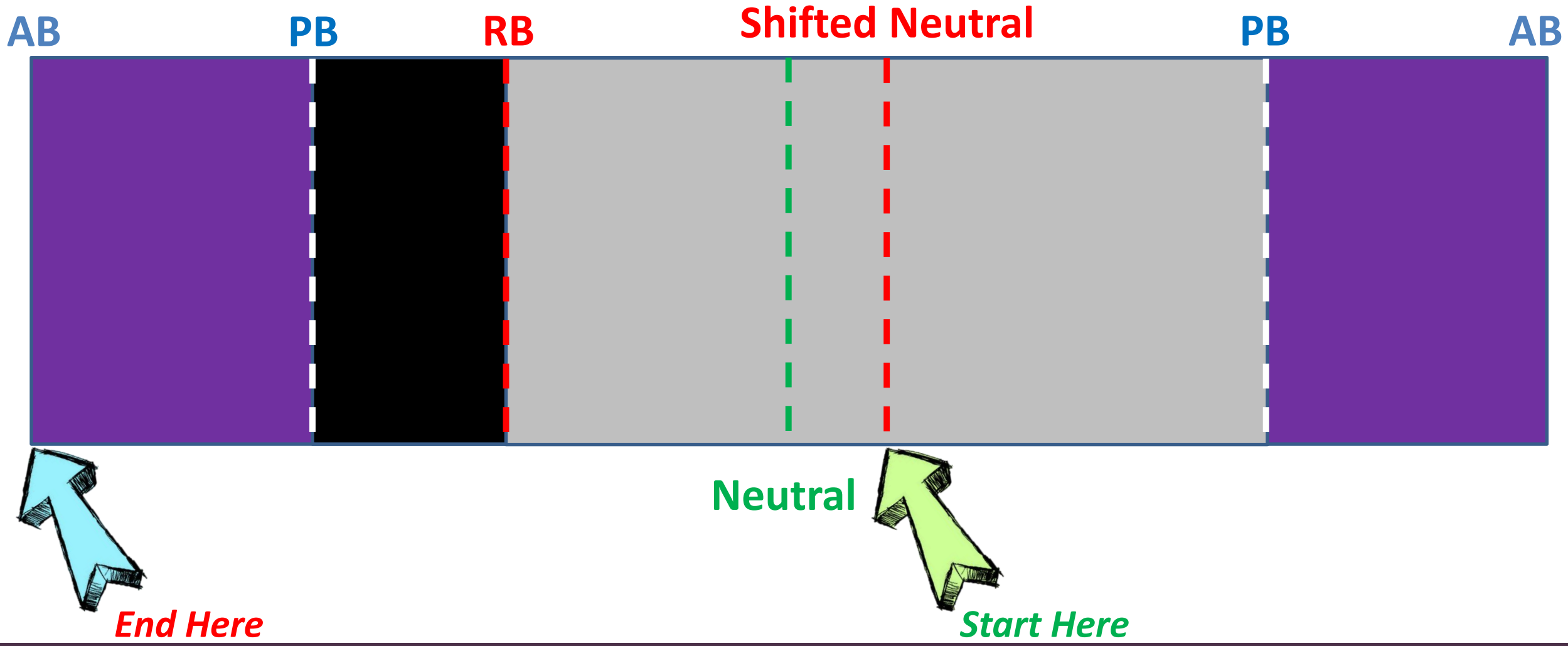

Supine Still Technique: OA
Dx: OA ERLSR

- **Initial Positioning:** Extend to localize to OA, then add rotation left and sidebending right
  - *Monitor at OA joint…near occipital condyle*
- **Localizing Force:** compression to the segment through hand contact on cranium
- **Activating Force:** Move OA through restrictive barrier through cranial hand contact *(FRRSL)* while maintaining compression
- **Final Positioning:** attained anatomic barrier
- *Return to neutral & retest*

Supine Still Technique: Typical Cervicals
Dx: C2 FRSR

- **Initial Positioning:** Flex to localize to C2, then add rotation right and sidebending right until TTA dissipates
  - *Monitor at articular pillar (Z-joint)*
- **Localizing Force:** compression to the segment through hand contact on cranium
- **Activating Force:** Move C2 through restrictive barrier *(ERSL)* using cranial hand contact while maintaining compression
- **Final Positioning:** attained anatomic barrier *ERSL*
- *Return to neutral & retest*

Start (C2 FRSR)

End (C2 ERSL)

Principles of Seated Cervical Functional Diagnosis

- **Monitor** the posterior aspects of the articular column of each vertebrae using the finger pads of your thumb and index just lateral to the SPs
  - *Starting at the suboccipital area and working inferiorly.*
- **Flex to Remove the Lordosis, then Evaluate Flexion/Extension** response introduced using your other hand on the crown of the patient's head
  - ***Increased TTA*** *response to motion indicates somatic dysfunction*
- **Segmental definition** by response to rotation and sidebending once the flexion or extension RBs have been engaged.

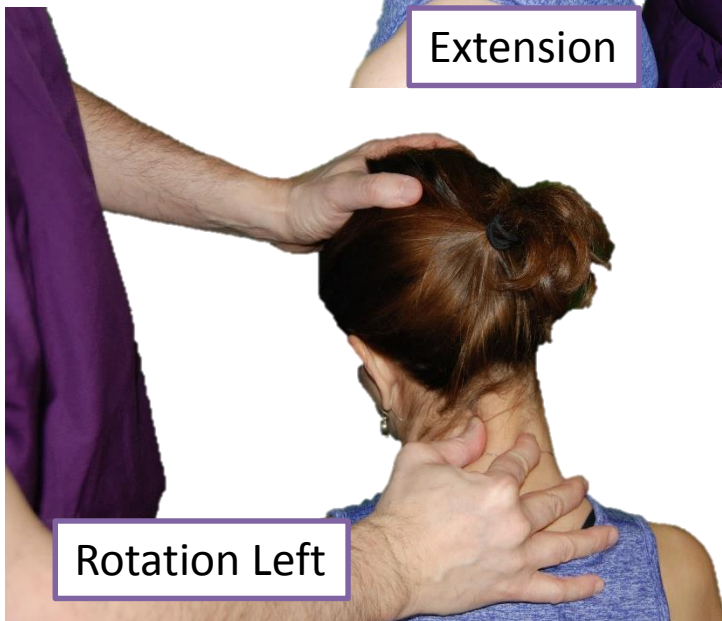

Seated MET Typicals – *Sidebending Focus*
Dx: C3 ERSR

1. **Monitor** the posterior aspects of the articular column using the finger pads of your thumb and index just lateral to the SPs.
2. **Engage the RB – *flex*** *first, then add sidebending and rotation*
3. **Patient directed sidebending away from RB** – held until tissue texture release is palpated (usually 3-7 seconds!)
4. Wait, then **move to next RB** and repeat steps 1-3 until no more releases are palpated
5. Re-evaluate

INR/MFR

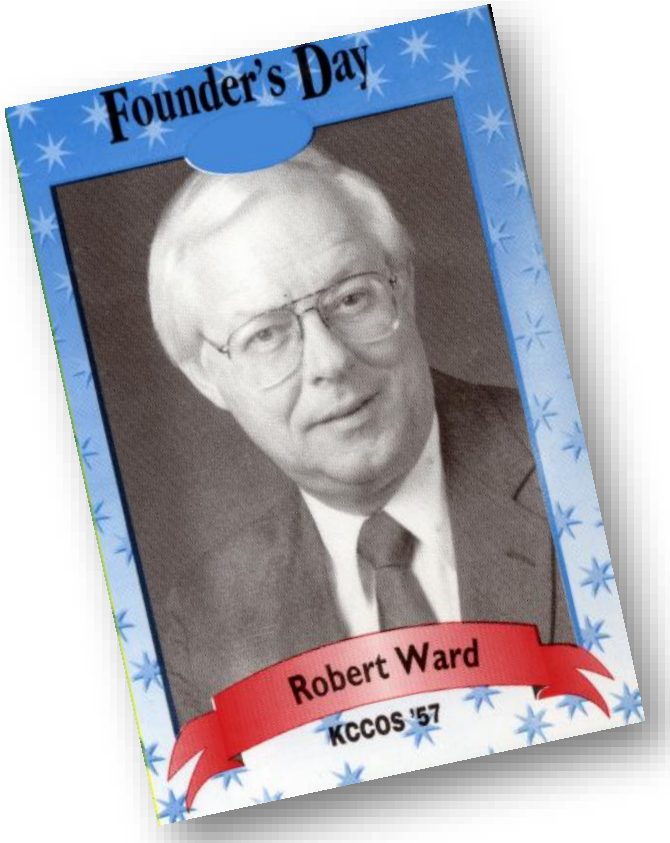

"For every tightness, there is a three-dimensionally related looseness. Commonly, the looseness is in exactly the opposite direction from the tightness."

-Robert Ward, DO, FAAO

Ward, Robert. Foundations of Osteopathic Medicine - 2nd Edition. LWW. Baltimore, MD 2002

INR/MFR

Sherrington's Law: ***When a muscle receives a nerve impulse to contract, its antagonists, receive, simultaneously, an impulse to relax.***

INR/MFR: Tight-Loose Relationship

A

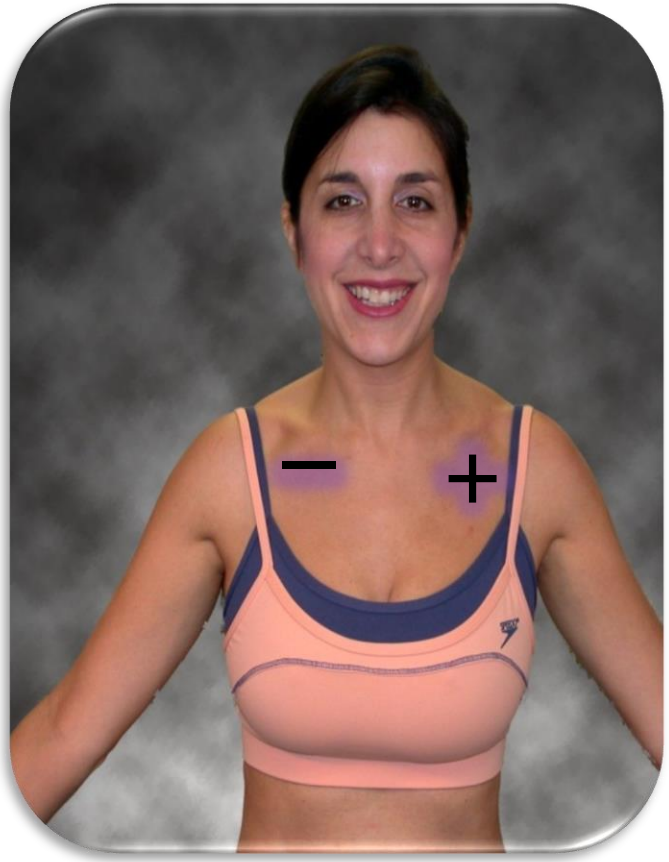

B

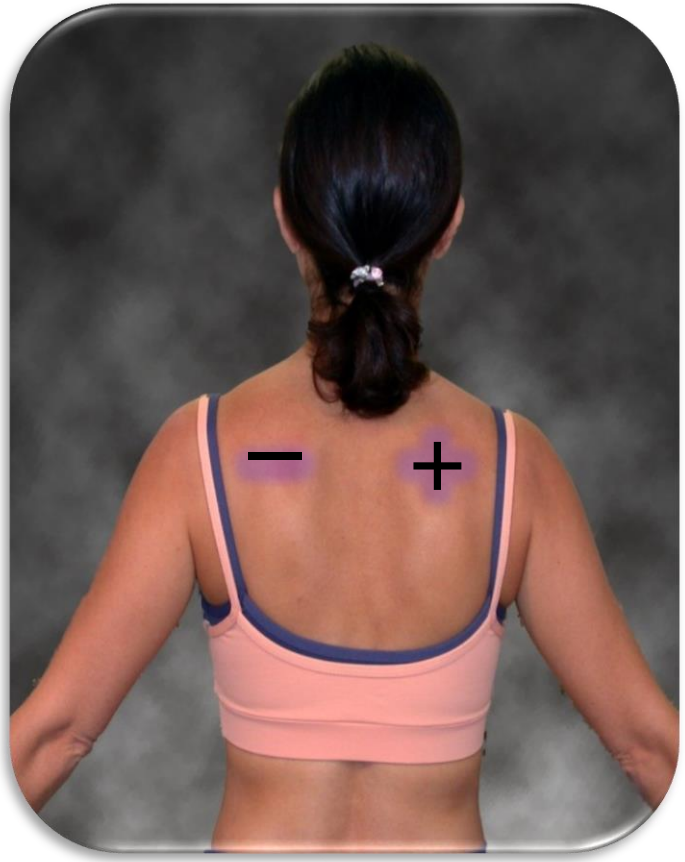

Key

+ = tight

- = loose

Danto, Jay B. *A Review of the Principles and Concepts of Integrated Neuromusculoskeletal Release and the Novel Application of a Segmental Anterior/Posterior Approach in the Thoracic, Lumbar and Sacral Regions* . JAOA. Vol 103: No 12 December 2003 583-596

MFR & INR Defined

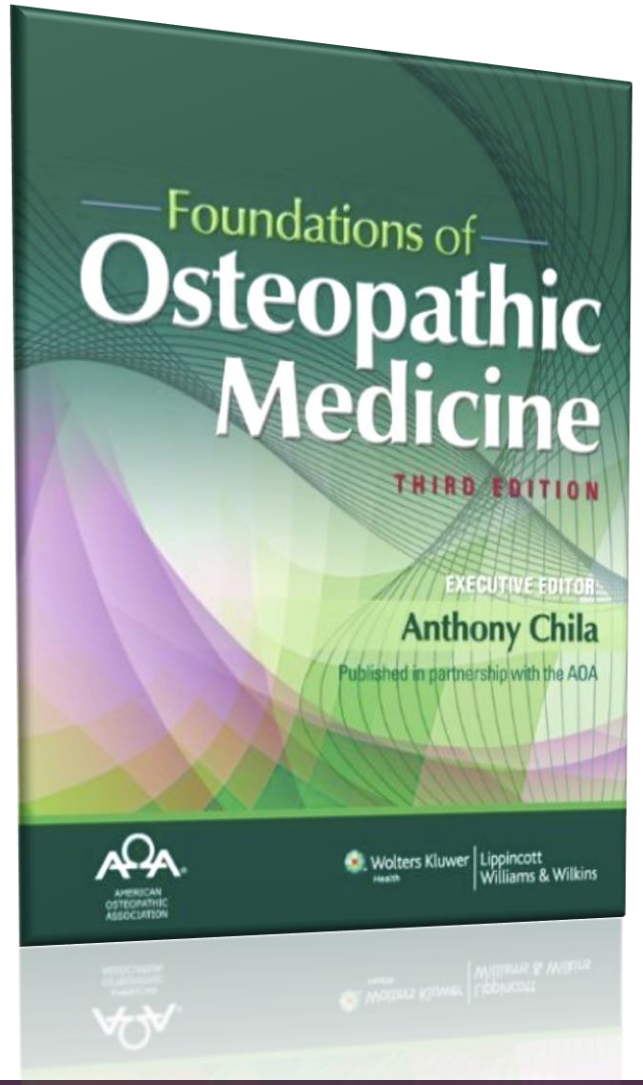

MFR

- A system of diagnosis & treatment first described by A.T. Still and his early students, which engages continual palpatory feedback to achieve release of myofascial tissues

INR (Integrated Neuromusculoskeletal Release)

- A treatment system in which combined procedures are designed to stretch & reflexively release patterned soft tissue & joint related restrictions

Chila, FOM3, 2010; p. 1097 – Glossary of Osteopathic Terminology (2009)

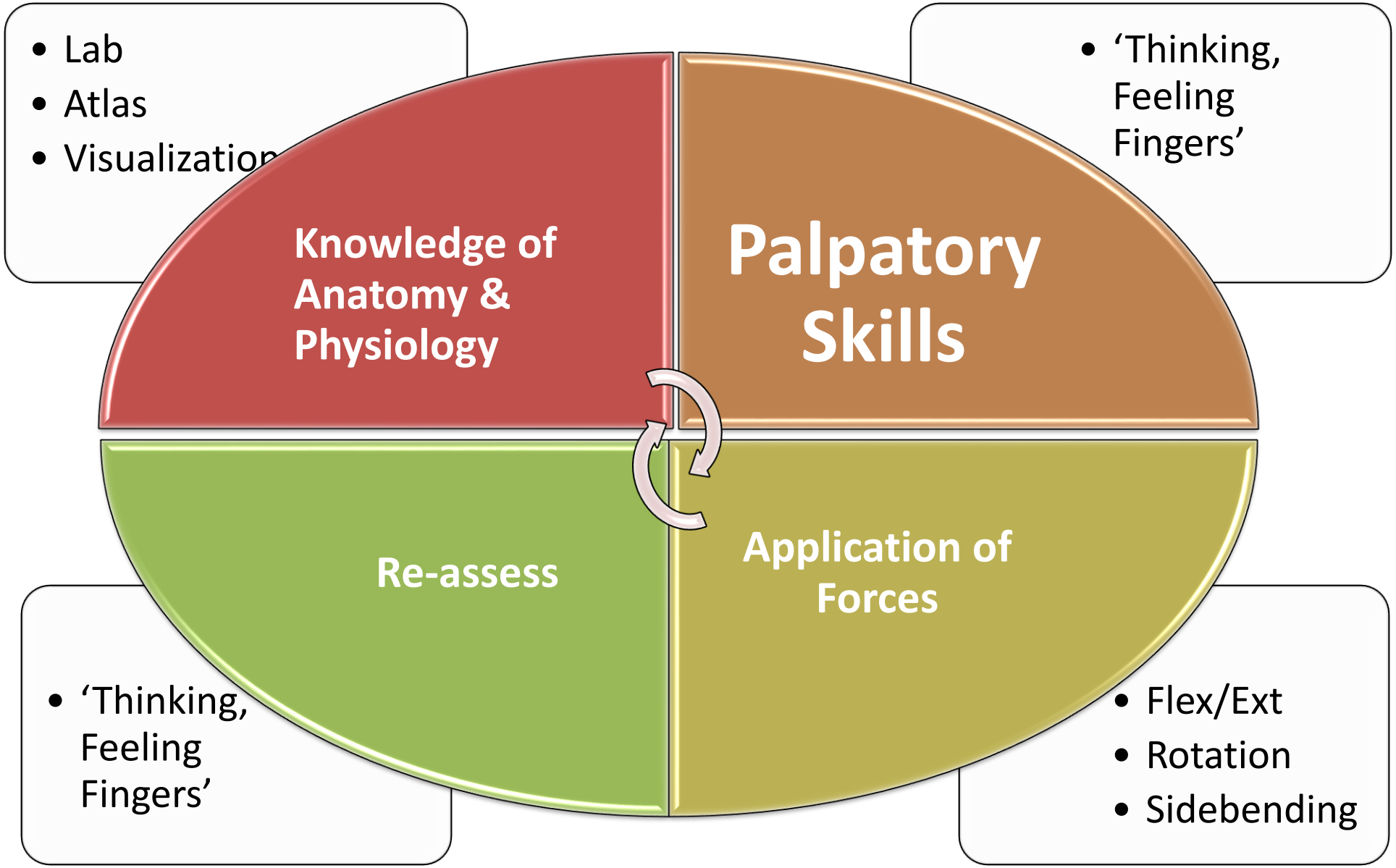

Application of MFR

Activating Forces

- **Inherent Forces**: using the body's PRM *(primary respiratory mechanism)*
- **Respiratory Cooperation**: Refers to a physician directed, patient performed, inhalation or exhalation or a holding of the breath to assist with the manipulative intervention.
- **Patient Cooperation**: the patient is asked to move in specific directions to aid in mobilizing specific areas of restriction

FOM3, p. 699

INR

REMs speed the treatment process:

- Breath holding
  - *The goal is to alter both intrathoracic & intraabdominal pressure using costodiaphragmatic, shoulder girdle & lumbopelvic interactions*
- Prone & supine simulated swimming & pendulum arm swing maneuvers as direct & indirect barriers are released.
- R/L cervical rotation
- Isometric limb & neck movements against the table, chair…
- Patient evoked movement from cranial nerves *(eye, tongue, jaw, oropharynx)*

Ward, FOM 2nd ed - 2003, p. 936

Indications for MFR

- Somatic dysfunction
  - *Almost all soft tissue or joint restrictions*
- When HVLA or muscle energy is contraindicated
  - *Consider indirect MFR*
- When counterstrain may be difficult secondary to a patient's inability to relax.

Contraindications of MFR

Absolute:

- Lack of Patient Consent
- Absence of Somatic Dysfunction

Relative:

- Infection of soft tissue or bone
- Fracture, Avulsion or dislocation
- Metastatic disease
- Soft tissue injuries: Thermal, Hematoma or Open wounds
- Post-op patient with wound dehiscence
- Rheumatologic condition involving instability of cervical spine
- DVT or Anticoagulation therapy

MFR Treatment Endpoint

- A three dimensional release is often palpated as:
  - *Warmth*
  - *Softening*
  - *Increased compliance/ROM*
- The continuous application of activating forces no longer produce change
- When finished, recheck of the tissue demonstrates symmetry

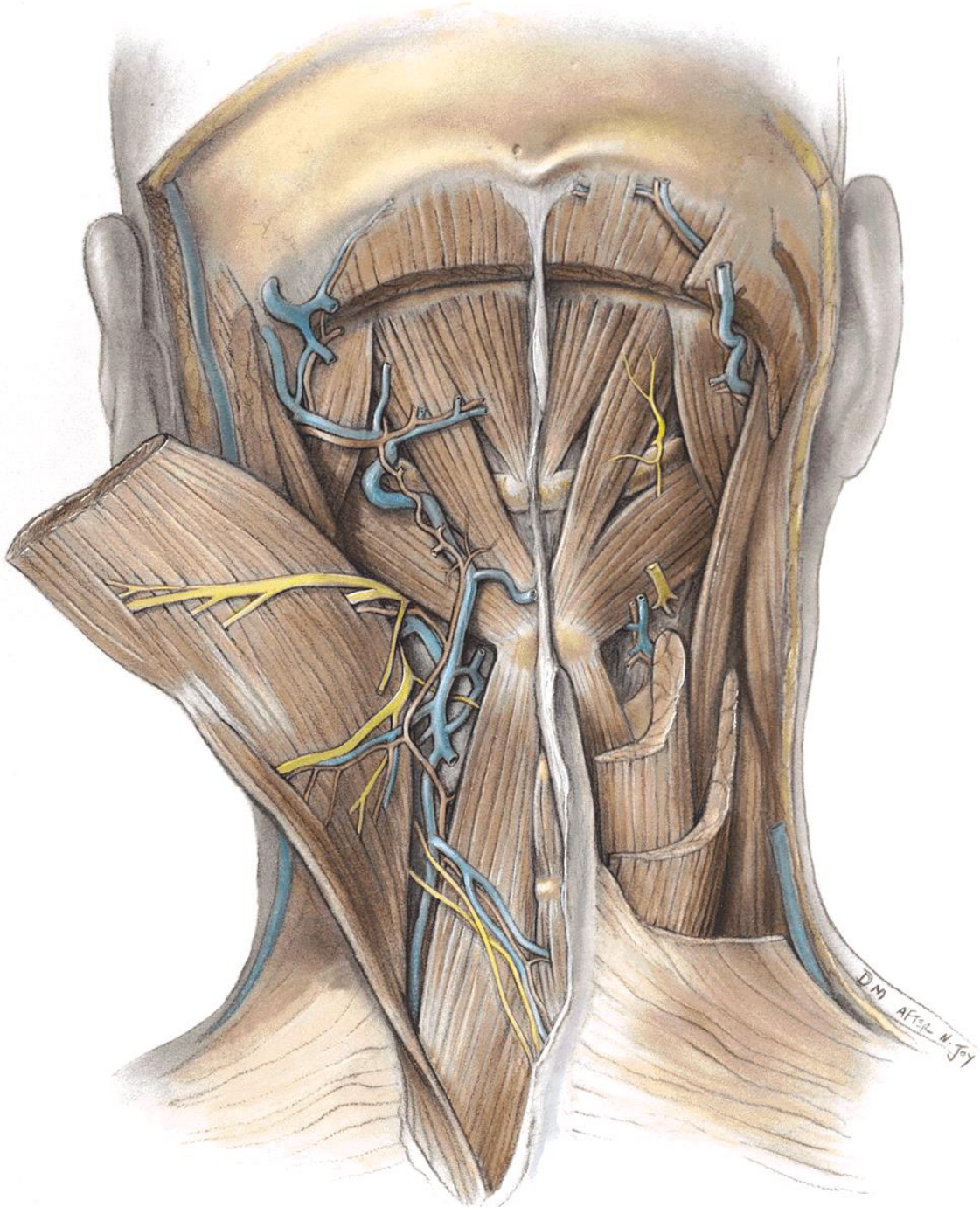
D.M. AFTEL M. JOY

Thoracic Inlet

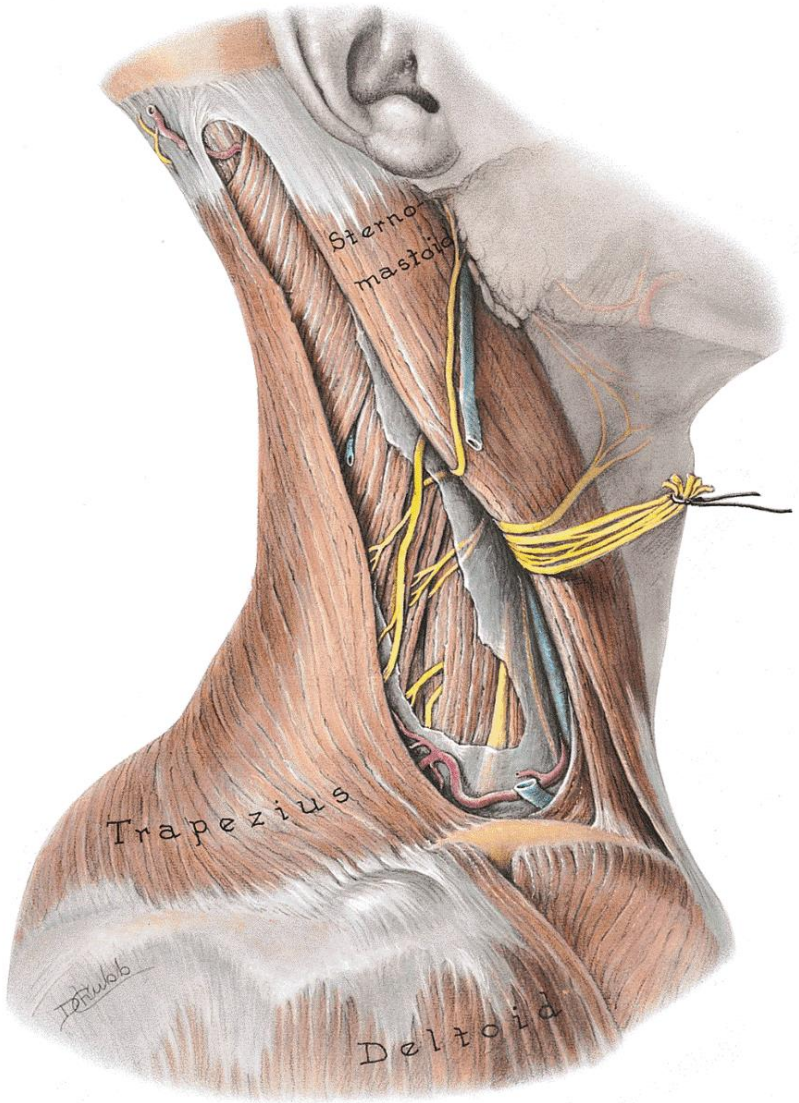

Cervicothoracic MFR/INR

1. *Physician's thumb pads rest posteriorly to the superior trapezii, finger pads are anterior and inferior to the clavicles (or as close as you can get to covering the broad area of the thoracic inlet)*
2. *Engage the RB in 3 planes*
   - ✓ ***Right/Left translation (rotation)***
   - ✓ ***Clockwise/Counterclockwise (sidebending)***
   - ✓ ***Possibly, Anterior/Posterior (flexion/extension)***
3. *The force is applied in a very gentle to moderate manner.*
4. *This force is held for 20 to 60 seconds or until a release is palpated. The physician may continue this and follow any additional release (creep) until it does not recur. Deep inhalation or other release-enhancing mechanisms can be helpful.*
5. *The physician reassesses the components of the dysfunction (TART).*

Dx & Tx of the T-spine & L-spine

Seated & Standing OMT

Motion Testing (T5-T12)

- Use trunk as a lever
- Monitor T5-T12
- Assess range and quality of motion in all planes

Seated Short Lever Intersegmental Motion Testing *(aka "Load & Spring")*

Static Positional Assessment (THORACIC & LUMBAR AREAS)

Layer palpate to the transverse processes. Note the position of the vertebra in space.

- **Rotation** is determined by the more posterior TP
- **Assess Extension:** ask the patient to extend by looking at the ceiling and have them stop when you palpation motion. F
- **Assess Flexion:** ask the patient to flex by looking down slowly and have them stop when you palpation motion.
- Based on the behavior of the transverse processes during the flexion, neutral, and extension movements, the posterior TP will either become more posterior (preference is the other motion), more equal (meaning that it is moving into it preferenced sagittal plane motion), or stay the same-ish in all sagittal plane motions (meaning its preference is for neutral).

Neutral

Flexion

Extension

Rotation Intersegmental "Load & Spring" (THORACIC AREA)

Apply ANTERIOR PRESSURE "springing" one side and then the other.

If resistance to rotation is observed on one side more than the other the vertebra is rotated to that side. Rr or Rl

Still Technique: Upper Thoracics (T1-4), Seated
Dx: T2 FRSR

- **Initial Positioning:** Extend to localize to T2, then add rotation right and sidebending right
  - *Monitor at TP for tissue texture normalization*
- **Localizing Force:** compression to the segment through hand contact on cranium
- **Activating Force:** Move T2 through restrictive barrier *(ERSL)* through cranial hand contact while maintaining compression
- **Final Positioning:** attained anatomic barrier *(ERSL)*
- *Return to neutral & retest*

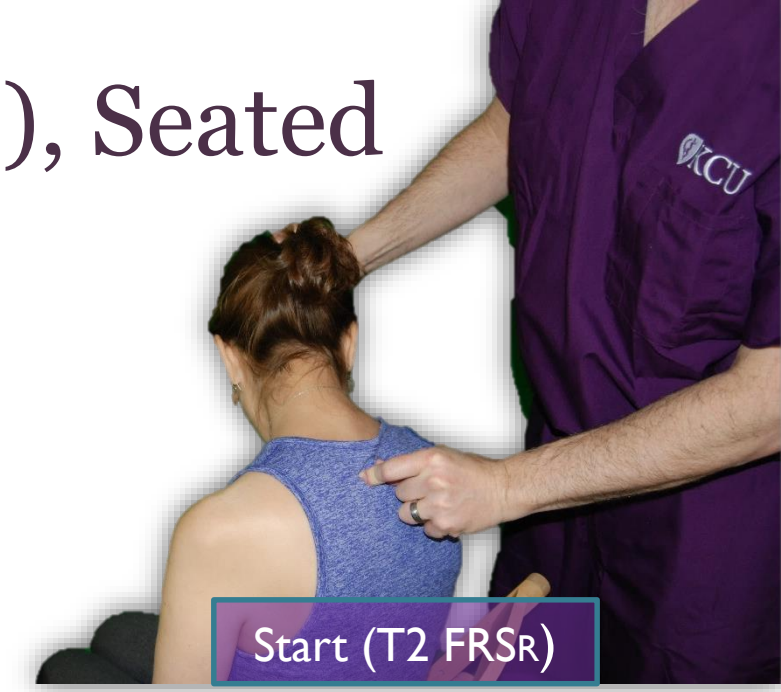

Start (T2 FRSR)


End (T1 FRLSL)

Still Technique: Lower Thoracics (T5-12)
Dx: T6 ERLSL

- **Initial Positioning:** Extend to localize to T6, then add rotation left and sidebending left
  - *Monitor at TP for tissue texture normalization*
- **Localizing Force:** compression through shoulders to the segment
- **Activating Force:** Move T6 through restrictive barrier through shoulder contact *(FRRSR)* while maintaining compression
- **Final Positioning:** attained anatomic barrier
- *Return to neutral & retest*


Start (T6 ERLSL)


End (T6 FRRSR)

Lumbar & Pelvic INR, Standing

- Physician contacts PSIS's with thenar eminence and iliac crests with fingers *(cognizant of patient's myofascial attachments involving the oblique abdominal obliques and lumbodorsal fascia)* **(A)**
- Engage fascia directly/indirectly with:
  - ***Anterior/Posterior Innominate Rotation***
  - ***Translation Right/Left***
  - ***Inflare/Outflare***
- REM's:
  - *Overhead with/without sidebending* ***(B)***
  - *Rotate arms right/left* ***(C)***
- Perform until no further release, re-evaluate.

Dx & Tx of the Pelvis *(sacrum and innominate)*

Seated & Standing OMT

Sacral Exam Landmarks

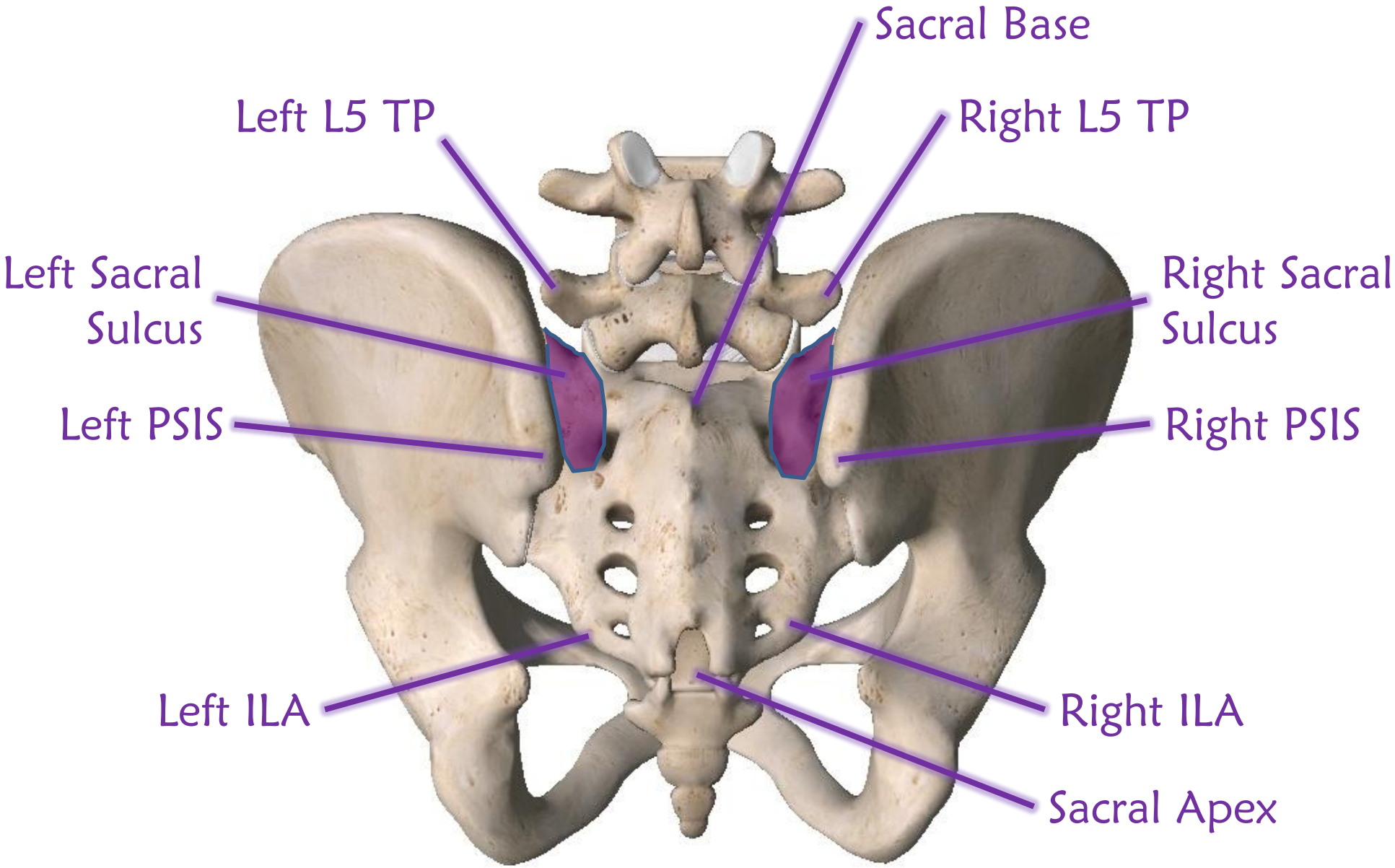

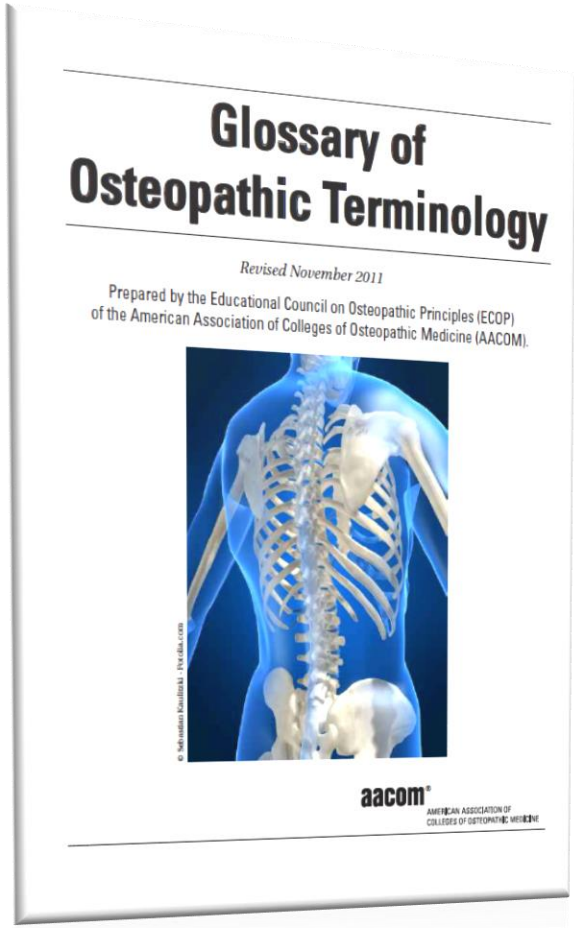

BLT Definition

1. According to Sutherland's model, all the joints in the body are balanced ligamentous articular mechanisms. *The ligaments provide proprioceptive information that guides the muscle response for positioning the joint, and the ligaments themselves guide the motion of the articular components.*

GOT 2011

BLT Technique

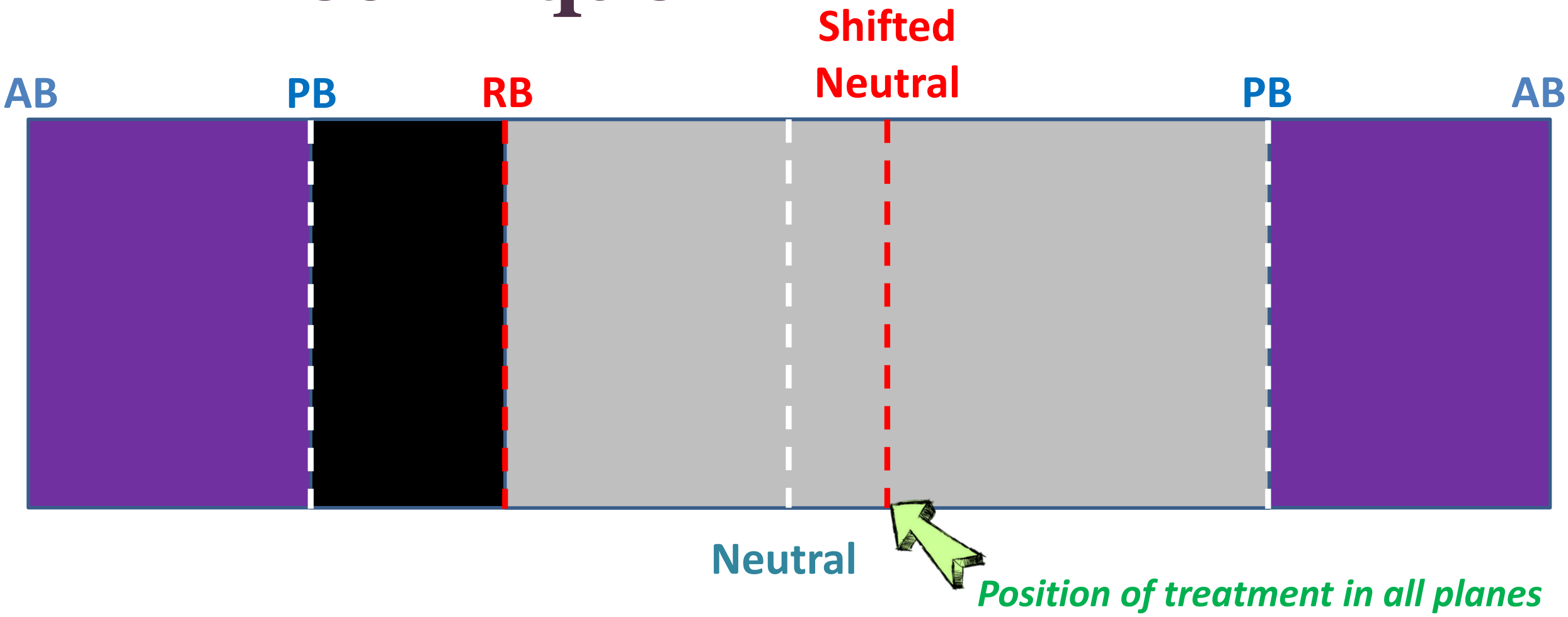

BLT Described by the Lippincott's

- "Osteopathic lesions are strains of the tissues of the body. When they involve joints it is the ligaments that are primarily affected so the term 'ligamentous articular strain' is the one preferred by Dr. Sutherland.
- The ligaments of a joint are normally on a balanced, reciprocal tension and seldom if ever are they completely relaxed throughout the normal range of movement… Since it is the ligaments that are primarily involved in the maintenance of the lesion it is they, not muscular leverage, that are used as the main agency for reduction….This is the point of balanced tension"

Lippincott. "Osteopathic Technique of Wm. G. Sutherland".1949 Year Book of the Academy of Applied Osteopathy

Seated Flexion Test

Thumbs placed below PSISs
& physician at eye level of PSISs

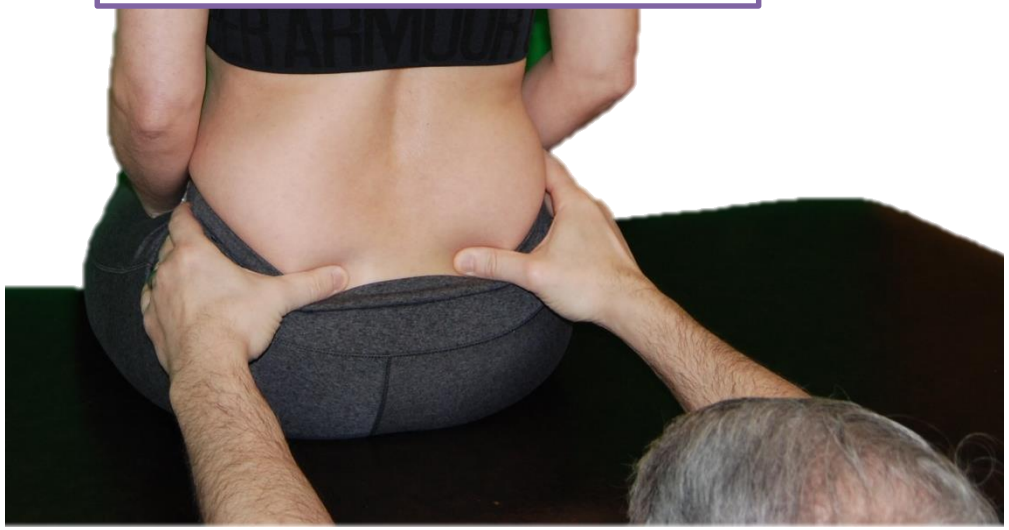

Positive Right means PSIS moves more superiorly on the right

Positive Test = one PSIS moves farther superiorly at the <u>end range of motion</u>

- *Usually the first side to move…too.*
- ***Axes** for torsions are opposite the positive side.*

BLT, seated
Dx: Right sacral torsion on a left axis

- Monitor the sacral sulci
- **Induce flexion from above** until the anterior sacral base is palpated as moving posterior to balance with the other side
- **Rotate the patient in the direction of the sacral rotation** through their upper body
- **Sidebending positioning** is based upon tissue texture response
- **Inhalation Activating Force:** held until air hunger
- Upon exhalation, recheck and repeat as needed until TART is significantly reduced

BLT, seated
Dx: Right sacral torsion on a Right axis

- Monitor the sacral sulci
- **Induce extension from above** until the posterior sacral base is palpated as moving anterior to balance with the other side
- **Rotate the patient in the direction of the sacral rotation** through their upper body
- **Sidebending positioning** is based upon tissue texture response
- **Exhalation Activating Force:** held until air hunger
- Upon inhalation, recheck and repeat as needed until TART is significantly reduced